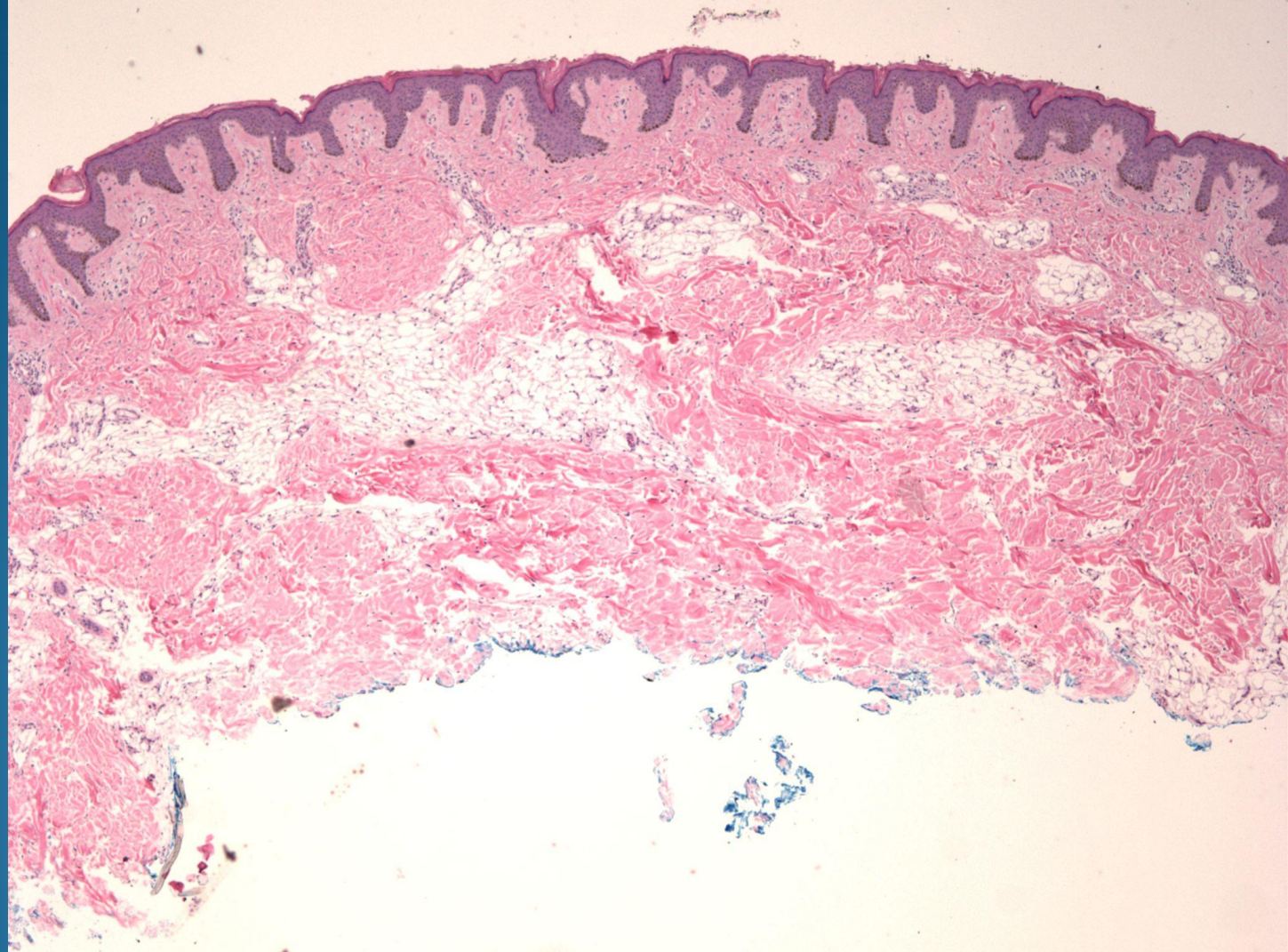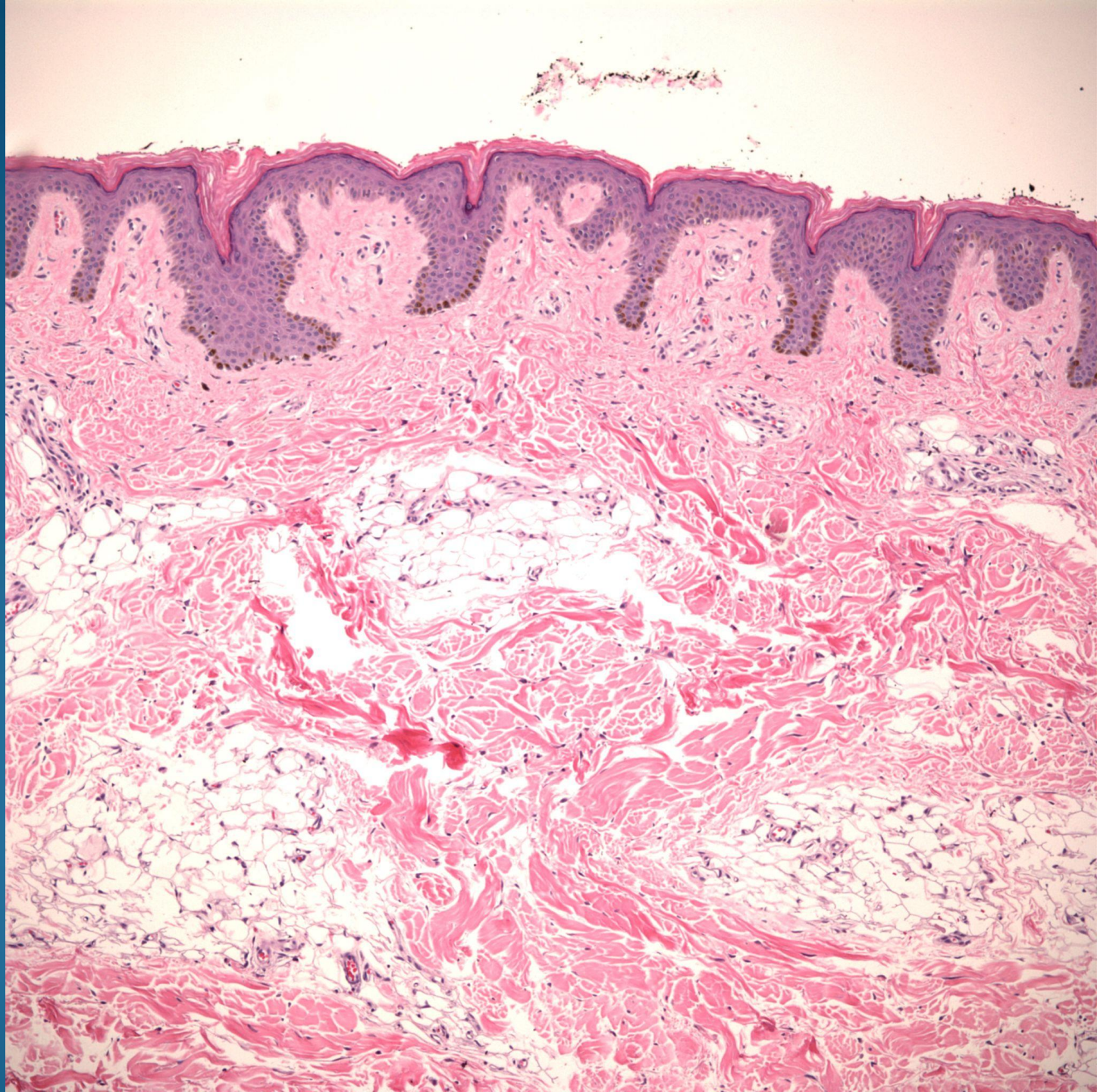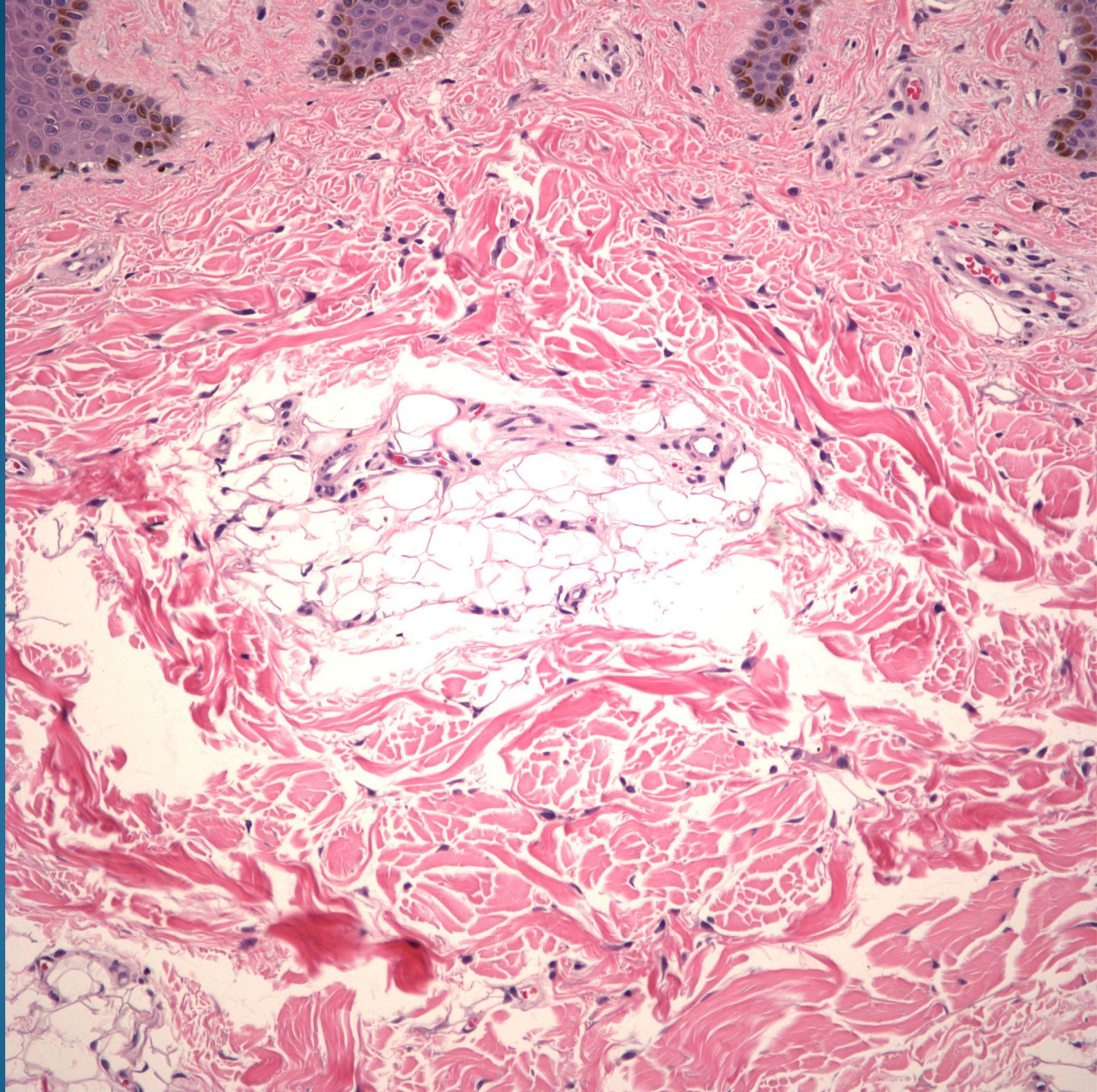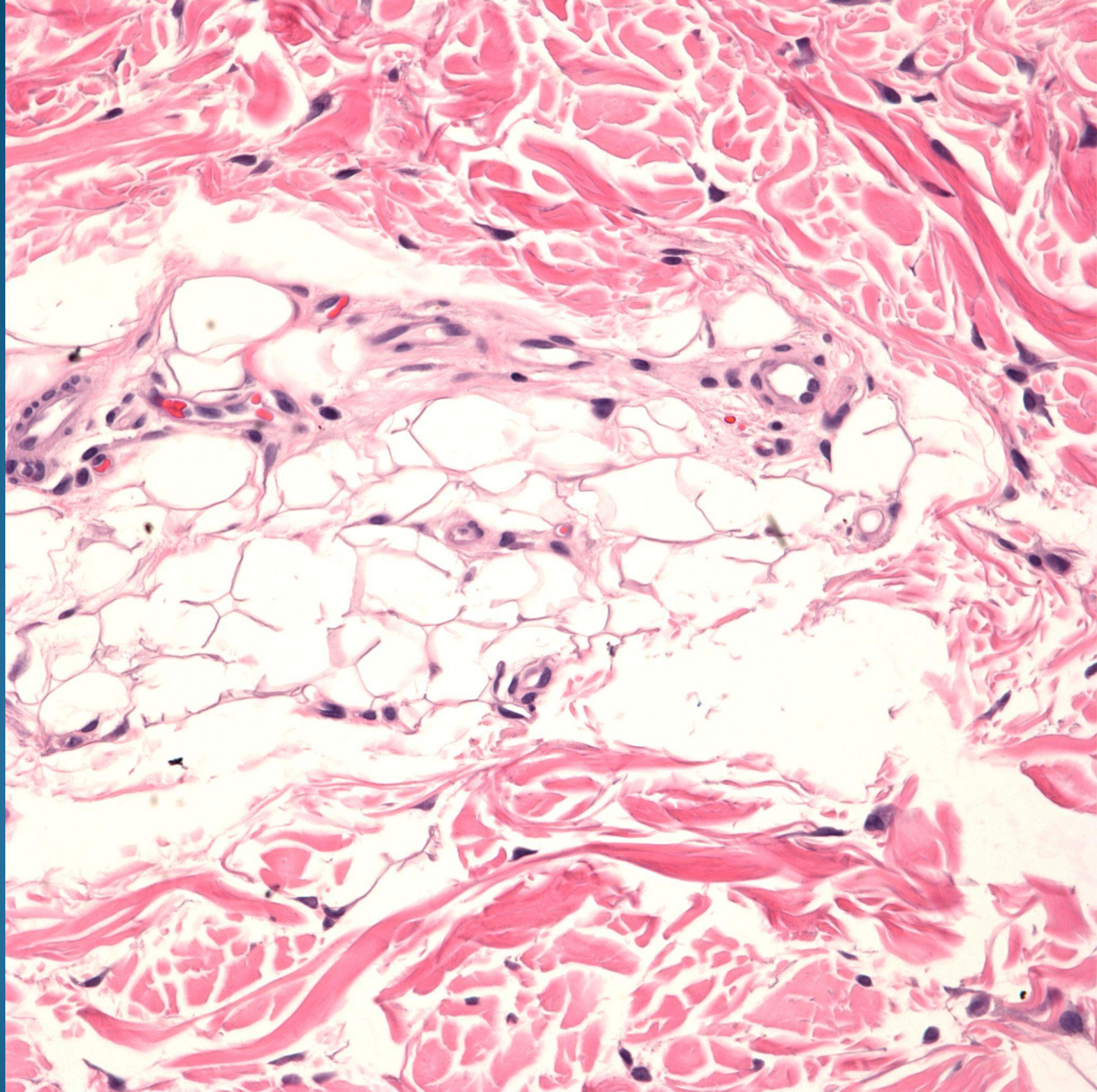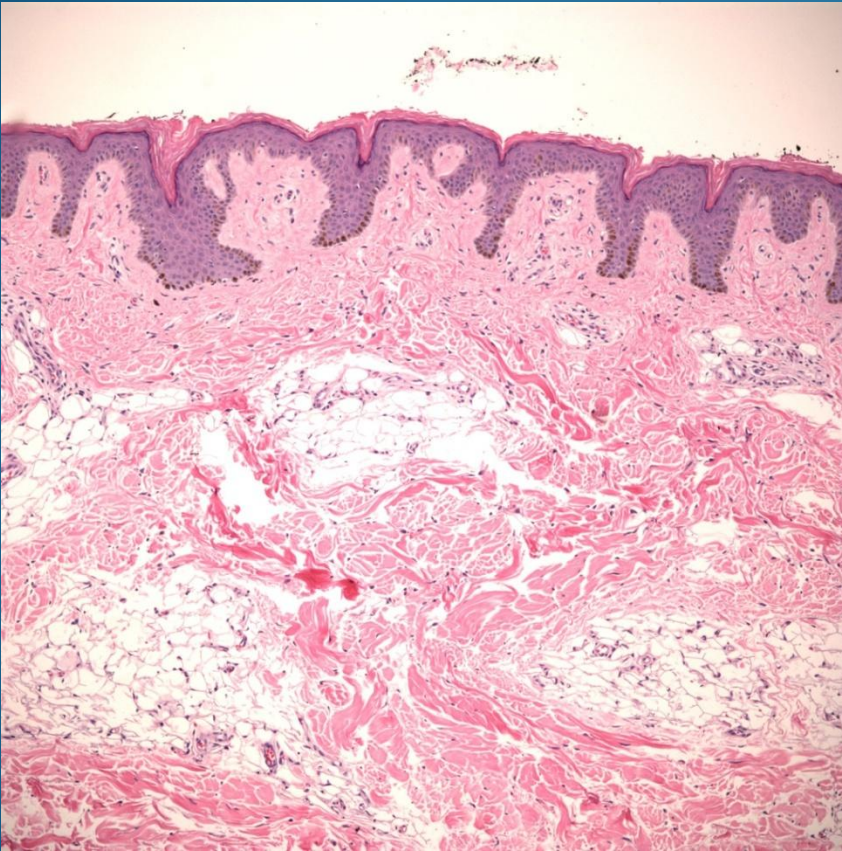


Nevus lipomatosis

Pearls



- Epidermal papillomatosis
- Mature adipose tissue extending into papillary dermis
- Clinical-pathological correlation
- DDX: Superficial lipoma